

---

# Lionfish Dissection: Techniques and Applications



NOAA Technical Memorandum NOS NCCOS 139



---

**Mention of trade names or commercial products does not constitute endorsement or recommendation for their use by the United States government.**

**Citation for this Report**

Green, S.J., Akins, J.L., and J.A. Morris, Jr. 2012. Lionfish dissection: Techniques and applications. NOAA Technical Memorandum NOS NCCOS 139, 24 pp.

---

---

# Lionfish Dissection: Techniques and Applications

Stephanie J. Green  
Department of Biological Sciences  
Simon Fraser University  
8888 University Drive  
Burnaby, British Columbia  
Canada, V5A 1S6

John L. Akins  
Reef Environmental Education Foundation  
98300 Overseas Highway  
Key Largo, Florida 33037

James A. Morris, Jr., Ph.D.  
Center for Coastal Fisheries and Habitat Research  
NOAA/NOS/NCCOS  
101 Pivers Island Road  
Beaufort, North Carolina 28516

NOAA Technical Memorandum NOS NCCOS 139  
2012



---

United States Department of  
Commerce

National Oceanic and  
Atmospheric Administration

National Ocean Service

John E. Bryson  
Acting Secretary

Jane Lubchenco  
Administrator

David M. Kennedy  
Assistant Administrator

---

## Table of Contents

INTRODUCTION .....	1
EUTHANASIA AND ANIMAL WELFARE .....	2
HANDLING PROCEDURES AND PRECAUTIONS .....	3
Dissection.....	3
Specimen disposal.....	3
First aid for envenomation .....	3
MEASUREMENT AND SAMPLING OVERVIEW .....	4
Minimizing measurement error.....	4
External anatomy .....	6
Internal anatomy .....	7
DISSECTION METHODOLOGY .....	8
External measurements and sampling.....	8
Weight.....	8
Length .....	8
Gape .....	9
Tissue sampling .....	9
Internal measurements and sampling.....	10
Opening the gut cavity .....	10
Gender identification and reproductive staging.....	12
Interstitial fat deposits.....	14
Stomach contents .....	14
Otolith removal .....	16
ACKNOWLEDGEMENTS .....	19
LITERATURE CITED .....	20
APPENDICES .....	21
I. Lionfish dissection specimen data sheet template .....	21
II. Lionfish stomach contents data sheet template.....	22
III. Dissection equipment list.....	23
IV. Lionfish tissue repository.....	24

## List of Figures

Fig. 1. Lionfish external anatomy.....	6
Fig. 2. Lionfish internal anatomy.....	7
Fig. 3. Taking external lionfish measurements: A) Lionfish weight measurement. Ensure the specimen is thoroughly blotted dry and that the entire specimen is balanced on the scale. B) Measuring lionfish total and standard length to the nearest 1 mm. The arrow indicates the location of the base of the caudal fin.....	9
Fig. 4. Measuring lionfish A) gape height and B) gape width to the nearest 1 mm. Ensure that the specimen's mouth is open to its fullest extent.....	9
Fig. 5. Sample collection of three tissue types for genetic and stable isotope research: A) gill, B) pectoral fin, and C) muscle tissue. Sample size for gill and fin tissue is a 1-cm <sup>2</sup> section; muscle tissue sample is a 1-cm <sup>3</sup> section.....	10
Fig. 6. Opening the lionfish's gut cavity. A) A shallow incision extends from the urogenital opening towards the base of the pelvic fins (pelvic girdle). B) As you approach the pelvic fins, a deeper cut will be required to sever the pelvic girdle. C) Cutting along the rear edge of the gill arch toward the dorsal fin. D) Lifting the flank to expose the gut cavity and internal organs, cutting through any minor connecting tissue as needed.....	11
Fig. 7. A) Removal of interstitial fat deposits from intestines and B) measuring interstitial fat volume to nearest 1 ml.....	14
Fig. 8. Stomach dissection and contents analysis. A) Using dissecting scissors sever the esophagus where it terminates. B) Insert scissors into the esophageal opening of the stomach. C) Make a shallow cut along the length of the stomach wall to the intestine opening. D) Invert the stomach and remove all prey items; placing prey onto a clean surface for sorting and identification.....	15
Fig. 9. Ontogenetic change in sagittal otolith shape, taken from lionfish of A) 250 mm, B) 325 mm and C) 357 mm total length.....	16

Fig. 10. Sagittal otolith removal. A) Sever the spinal cord between the head and the first dorsal fin ray. B) Grasp the gill filaments and arches and sever their attachment to the roof of the oral cavity. C) Locate the cranial cavity by running two fingers along both sides of the spinal cord anteriorly until a slight bulge is felt. D) Make a cut on the posterior side of the cavity down through the spine. This incision allows access to the otic bulba, which contains the sagittal otoliths. E) Brain matter (white, soft tissue) will often be exposed by opening the cranial cavity. F) Reach gently into the cranial cavity to remove the free-floating otoliths.....18

### **List of Tables**

Table 1. Dissection activities and some of the primary uses of data generated by each type of measurement or sample. Scientific measurements are generally expressed in metric units, allowing for universal comparison (i.e., millimeters [mm], milliliters [ml] and grams [g]).....4

Table 2. Sex determination and gonad staging key for lionfish.....13

Table 3. Five-point scale for scoring the digestion of prey items removed from a lionfish stomach.....16

## INTRODUCTION

### The Goals of Dissection

Dissection can provide unique information on the physiology, biology and ecology of organisms. This document describes protocols for dissecting lionfish (*Pterois volitans* and *P. miles*). Protocols were developed to provide guidance to trained research personnel. Lionfish are native to the Indo-Pacific, but have become established in marine habitats within the Western Atlantic, Gulf of Mexico and Caribbean. The protocols described within this document were designed to help standardize handling and dissection methodologies for these species, with the goal of improving the coordination of research (e.g., Lionfish Tissue Repository; Appendix V). We focus on dissection methods, which yield data that contribute to our understanding of lionfish biology and ecology. By pairing dissection information with environmental and biotic data, researchers and managers can better understand lionfish population structure and dynamics, age and growth, reproductive biology, and food web ecology on various temporal and spatial scales.

### Population structure

The structure of populations can be determined through genetic approaches, which use tissue samples collected from dorsal fin, caudal fin, gill, and muscle tissues.

### Population dynamics

Age and growth information from individual fish can be determined using otoliths (ear stones) in conjunction with fish body lengths. The relationship between weight and length of lionfish specimens can also be used to monitor changes in body condition, which may correlate with environmental variables such as: habitat type, resource availability, changing latitude, or invasion status. These data can also be used to determine temporal and spatial changes in age structure of local populations.

### Reproductive biology

The reproductive status of an individual lionfish can be determined using various metrics such as gonad weight, morphology, and histology. These data aggregated over space and time can yield population-level trends in reproductive biology, such as spawning frequency and seasonality, and maturation schedules.

### Food web ecology

Lionfish diet can be characterized by identifying and measuring the stomach contents of collected specimens. Conducting stomach contents analysis across temporal and spatial scales can improve our understanding of changes in diet composition and potential community effects. The carbon and nitrogen isotopic signature of lionfish muscle and fin tissues can be used to assess trophic position and feeding ecology. These data can be used in conjunction with isotope

data from native species to describe biotic interactions between lionfish and members of the invaded food web.

## **EUTHANASIA AND ANIMAL WELFARE**

Many organizations such as universities, government agencies and scientific journals have strict standards for the humane treatment of animal taxa used in scientific study. These standards apply to methods by which death is caused in specimens destined for dissection. Euthanasia is the act of inducing humane death in an animal (American Veterinary Medical Association, 2007). At all times, research personnel should ensure that euthanasia is performed in an ethical manner to minimize pain and distress to the specimen. Euthanasia of lionfish specimens can be achieved through several methods, depending on the resources available and the intended use of the fish.

### **Euthanasia methods**

The following euthanasia methods are appropriate for live-captured specimens. For information on techniques for live capture please refer to Akins (*in press*).

#### **Eugenol**

If lionfish specimens are not destined for human consumption, they can be euthanized using an overdose of eugenol (clove oil and isopropyl alcohol; in accordance with Borski and Hodson 2003). Typical response includes rapid swimming followed by loss of equilibrium and inverted floating at the surface. Death is marked by the cessation of opercular (gill) movement for a period exceeding 5 minutes. Clove oil overdose refers to the exposure of a fish to a concentration greater than that required for anaesthesia ultimately resulting in death. These doses have been described in the literature for numerous body sizes and fish species (Borski and Hodson 2003; Neiffer et al. 2004; Soltani et al. 2004). Collectively or individually, fish should be transferred directly to a solution of 10 L seawater and 50 ml/L eugenol (a mixture of 1/10 clove oil and 9/10 alcohol by volume; 5 ml clove oil and 45 ml alcohol per liter of seawater or 50 ml clove oil and 450ml for 10L seawater). Lionfish response to this treatment is rapid; cessation of gill movement generally occurs within 5 minutes of exposure to the solution.

#### **Ice slurry**

In cases where the lionfish meat is destined for human consumption, the handler may immerse the lionfish in an ice-seawater slurry for approximately 15 min. Exposure to low temperatures decreases the heart rate of lionfish to the point of death (Wilson et al. 2009; Blessing et al. 2010).



## **HANDLING PROCEDURES AND PRECAUTIONS**

### **During dissection**

Lionfish spines can remain venomous for some time after death (depending on temperature) and those who handle lionfish must take extra precautions to protect themselves from envenomation (Badillo et al. 2012). Aside from their venomous nature, a lionfish's dorsal, pelvic and anal spines can pose a risk because they are needle sharp (Fig. 1). When handling both live and euthanized lionfish, it is prudent to wear puncture resistant gloves to reduce the risk of envenomation. The symptoms of envenomation include pain and swelling in the affected appendage, but could include sweating, respiratory distress and even temporary paralysis in more severe cases (Badillo et al. 2012). Puncture resistant gloves manufactured by Hex Armor®, TurtleSkin®, and other specialty companies are designed specifically to prevent needle-stick and other types of industrial punctures. Heavy leather or canvas work gloves, latex or nitrile examination gloves are not suitable substitutes as lionfish spines can easily penetrate these materials. When using protective equipment, follow the manufacturer's instructions and be cognizant of the area of protection. Some gloves may only provide protection in the palm and fingers.

Before dissection begins (following completion of any weight and length measurements), the lionfish's spines can be removed with a sharp pair of scissors or knife. Cutting the spines off at their base can minimize risk of envenomation. Protection against skin irritation caused by the non-venomous spines (opercular spines or cheek mail; Fig. 1H) on lionfish heads can be provided by wearing protective gloves made of nitrile, latex, or more durable rubber compounds.

### **Specimen disposal**

Following dissection, care should be taken to ensure that lionfish carcasses, including spines, are safely handled and disposed. Discarded lionfish parts that contain venomous spines should be placed in stout, puncture-proof, and capped containers such as a glass or plastic jar or bottle to avoid possible envenomation during waste handling. Carcasses containing venomous spines should not be placed back into near-shore or high visitation marine environments as currents may bring the carcasses back into public areas.

### **First aid for envenomation**

In the event of a lionfish sting, immediate first aid treatment includes immersion of the affected area in non-scalding hot water until pain subsides. Secondary medical treatment may be advised, as symptoms and complications vary depending on the severity of the sting, whether or not part of the spine remains in the wound, and individual reactions to lionfish venom. Further information on lionfish stings and their treatment can be obtained at <http://www.reef.org/lionfish> (REEF 2012) or <http://www.ccfhr.noaa.gov/stressors/lionfish.aspx> (NOAA 2012).

## MEASUREMENT AND SAMPLING OVERVIEW

This dissection protocol is comprised of a series of measurement and sampling methodologies, most easily conducted in a specific sequence. We broadly group these methodologies by ‘external’ and ‘internal’ sampling. A quick reference guide is provided in Table 1 with additional detail in the following sections.

Table 1. Dissection activities and some of the primary uses of data generated by each type of measurement or sample from juvenile and adult lionfish. Scientific measurements are generally expressed in metric units, allowing for universal comparison (i.e., millimeters [mm], milliliters [ml] and grams [g]).

	Type	Metric	Units	Application
External	Measurement	Total length (TL)	mm	Growth, body condition, population size structure
		Standard length (SL)	mm	
		Weight	g	
	Sample	Gape width	mm	Feeding ecology
		Gape height	mm	
		Gill tissue	-	Species identification, population structure
		Muscle tissue	-	Food web ecology through stable isotope analysis, species identification, population structure
Internal	Measurement	Fin clip		Species identification, population structure
		Gender	M or F	Individual gender, gender ratio in population
		Interstitial fat volume	ml	Health assessment
	Sample	Stomach contents	mm & ml	Feeding ecology
		Otoliths	-	Age and growth
		Gonad	-	Reproductive physiology
		Stomach contents	-	Feeding ecology

**Minimizing measurement error**

Small amounts of measurement error can greatly influence the biological interpretation of data collected during dissection. It is important that the dissector execute each measurement carefully, paying close attention to detail, in order to minimize error. When possible, having a separate data recorder increases the efficiency of the data collection process and reduces recording error. When a separate recorder is used, verbally confirming each measurement by repeating it back to the dissector ensures the highest quality data. Original hard copies of data entry should always be archived for future reference. In all cases, the units of measurement should be recorded (e.g., mm, g, ml). Pre-labeling all sample vials and bags with sample identification improves efficiency and decreases cross-contamination. Additional sources of error, specific to each measurement are described in the following section. Sample data sheets are provided in Appendices I and II.

## EXTERNAL ANATOMY

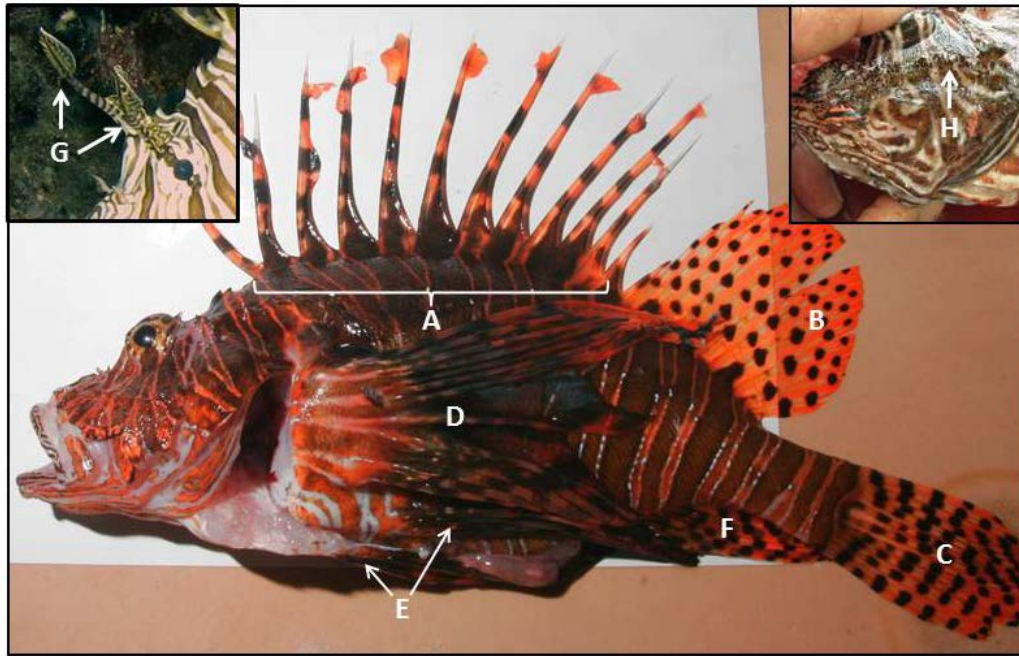


Fig 1. Lionfish external anatomy. Photo credit C. Calloway (main photo).

Code	Description	Venomous	Notes
A	Dorsal spines	Yes	13 spines, all are venomous
B	Soft dorsal	No	Secondary dorsal fin; non-venomous
C	Caudal fin	No	Non-venomous
D	Pectoral fin	No	Non-venomous
E	Pelvic fin	Yes	First spine on each pelvic fin is venomous
F	Anal fin	Yes	The first three spines of the anal fin are venomous
G	Super-ocular tentacles	No	Missing in this specimen; <i>left inset</i>
H	Opercular spines	No	Larger individuals may have prominent bony protrusions on the operculum and head; <i>right inset</i> , also referred to as "cheek mail"

## INTERNAL ANATOMY

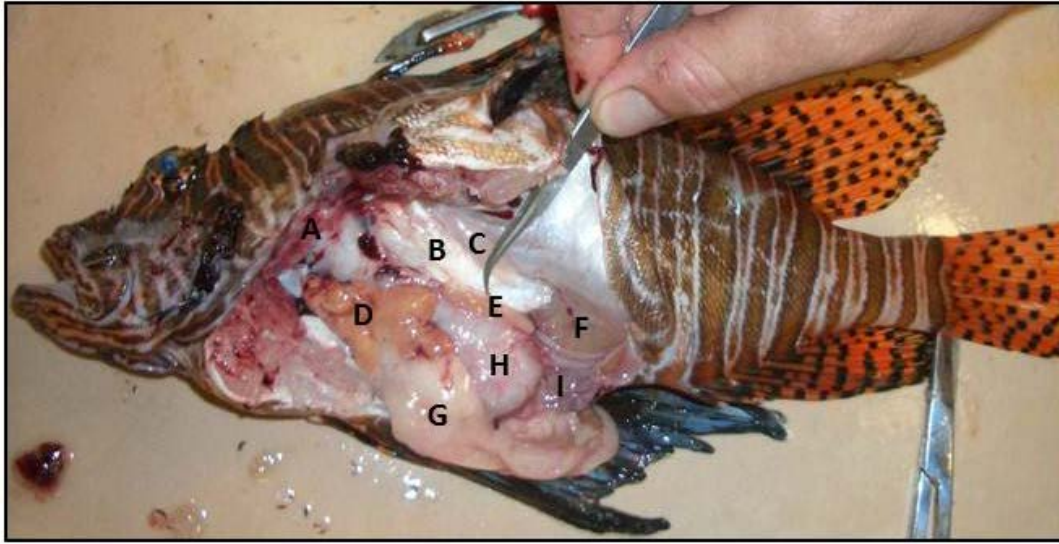


Fig 2. Lionfish internal anatomy.

Code	Description	Notes
A	Gill rakers and filaments	
B	Swim bladder	Often over inflated in specimens brought up from depth; may be deflated in speared fish
C	Swim bladder muscles	Used to control position of swim bladder, often confused with gonads in smaller specimens
D	Liver	Color can be an important indicator of health
E	Gonad (this specimen: testis)	Often lay along inflated swim bladder Two gonads; second in same position on the other side of the body; Males: testes are thin and elongated with edges Females: ovaries are rounded. Size depends on development (see additional photographs figures below)
F	Urinary bladder	Clear membrane, usually only visible when filled with urine; Easily ruptured during dissection
G	Interstitial fatty deposits	White tissue, often surrounding stomach and intestines
H	Stomach	Can expand up to ~30 times when full
I	Intestine	Often contains dark-colored digested matter

## **DISSECTION METHODOLOGY**

### **External measurements and sampling**

#### **Weight**

Before weighing the lionfish, place your weight boat or specimen tray on the scale and tare it. Blot the lionfish dry using paper towel, as excess water can be a large source of error. If the specimen has been euthanized in ice slurry, check the mouth cavity for any remaining ice. When balancing the lionfish on the scale, ensure that no portion of the fish is touching the table (Fig. 3A). Read and record the unit weight measurement in grams.

Note: When possible, do not take weight measurements on a moving surface (i.e., boat) as the movement of the vessel will make accurate weight measures difficult.

#### **Length**

Use a metric fish board or metric measuring tape secured to a flat surface for all length measurements, and be sure to place the lionfish ON TOP of the measuring tape. The tape should run parallel to the fish's midline from snout to tail (Fig. 3B). Placing the measuring tape on top of the fish introduces measurement error due to curvature of the tape. To measure total length (TL), obtain fish length from the tip of the snout to the longest point on the tail (caudal fin), recording to the nearest 1 mm (Fig. 3B). Ensure that the specimen's mouth is closed during measurement. Measure standard length (SL) as the length from the tip of the snout to the last vertebrae to the nearest 1 mm. The last vertebra is at the base of the end of the fleshy portion of the caudal peduncle (Fig. 3B) and can be located with manual probing or by flexing the caudal peduncle to find the last vertebrae.

Note: Accuracy of weight and length measurements may decrease once fish body cavities have been opened or altered (through filleting or other handling procedures). These conditions should be noted in any altered specimens.




Fig. 3. A) Lionfish weight measurement. Ensure that the specimen is thoroughly blotted dry and that the entire specimen is balanced on the scale. B) Measuring lionfish total and standard length to the nearest 1 mm. The arrow indicates the location of the base of the caudal fin.

### Mouth gape

To measure gape size, open the mouth of the lionfish to its fullest extent (without overextending). With a ruler, measure the distance (to the nearest 1 mm) between the inside of the bottom jaw and inside of the top jaw (*gape height*; Fig. 4). Next, measure the distance (to the nearest 1 mm) across the width of the mouth (*gape width*).

Note: Gape measurements and relationships to body length may be available in published literature in the future.

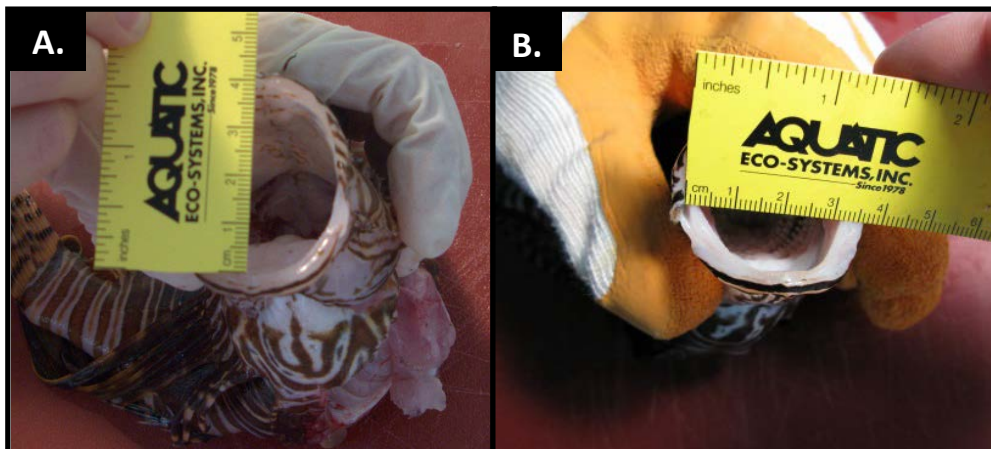


Fig. 4. Measuring lionfish A) gape height and B) gape width to the nearest 1 mm. Ensure that the specimen's mouth is open to its fullest extent.

### Tissue sampling

When collecting tissues for genetic purposes, it is important not to contaminate samples. Ensure that all dissection equipment (i.e., scissors, scalpels, forceps) are cleaned with ethanol or DNA Zap™ (preferred) prior to taking each sample. All the tissues listed below will provide ample DNA for genetics studies and can be placed in fixative (ethanol or DMSO buffered solution) or frozen (Kelsch and Shields 1996). The ratio of fixative to tissue should be 50:1 for



proper fixation. If the tissue is intended for use in stable isotope analysis, store frozen (without fixative) in an air-tight sample container.

*Gill tissue:* Using dissection scissors, remove a 1-cm<sup>2</sup> section of gill tissue from an inside arch including both arch and filament (Fig. 5A).

*Fin clip:* Remove a 1-cm<sup>2</sup> section of pectoral fin, including membrane using dissection scissors or a scalpel (Fig. 5B).

*Muscle tissue:* Using dissection scissors or scalpel, dissect a 1-cm<sup>3</sup> section of white muscle tissue (including skin) from the shoulder of the fish (behind the head and above the lateral line; Fig. 5C).



Fig. 5. Sample collection of three tissue types for genetic and stable isotope research: A) gill, B) pectoral fin, and C) muscle tissue. Sample size for gill and fin tissue is 1-cm<sup>2</sup> section; muscle tissue sample is 1 cm<sup>3</sup>.

## Internal measurements and sampling

### Opening the gut cavity

Using dissection scissors, make a shallow incision from urogenital opening towards the base of the pelvic fins (pelvic girdle) along the ventral surface of the fish (Fig. 6A). Take care to cut shallowly; lifting up with scissors will extend the tissue away from organs helping to avoid damage to the internal organs. As you approach the pelvic fins, a deeper cut will be required to sever the pelvic girdle. A pair of utility scissors may be needed to sever the pelvic girdle in larger specimens. Continue cutting anteriorly beyond the pelvic girdle to the isthmus of the gill openings and snip through the thin flesh of the isthmus (Fig. 6B). Next, place the fish on its side and cut along the rear edge of the gill arch toward the dorsal fin (Fig. 6C). Finally, lift the lateral musculature to expose the gut cavity and internal organs, cutting through any minor connecting tissue as needed (Fig. 6D).



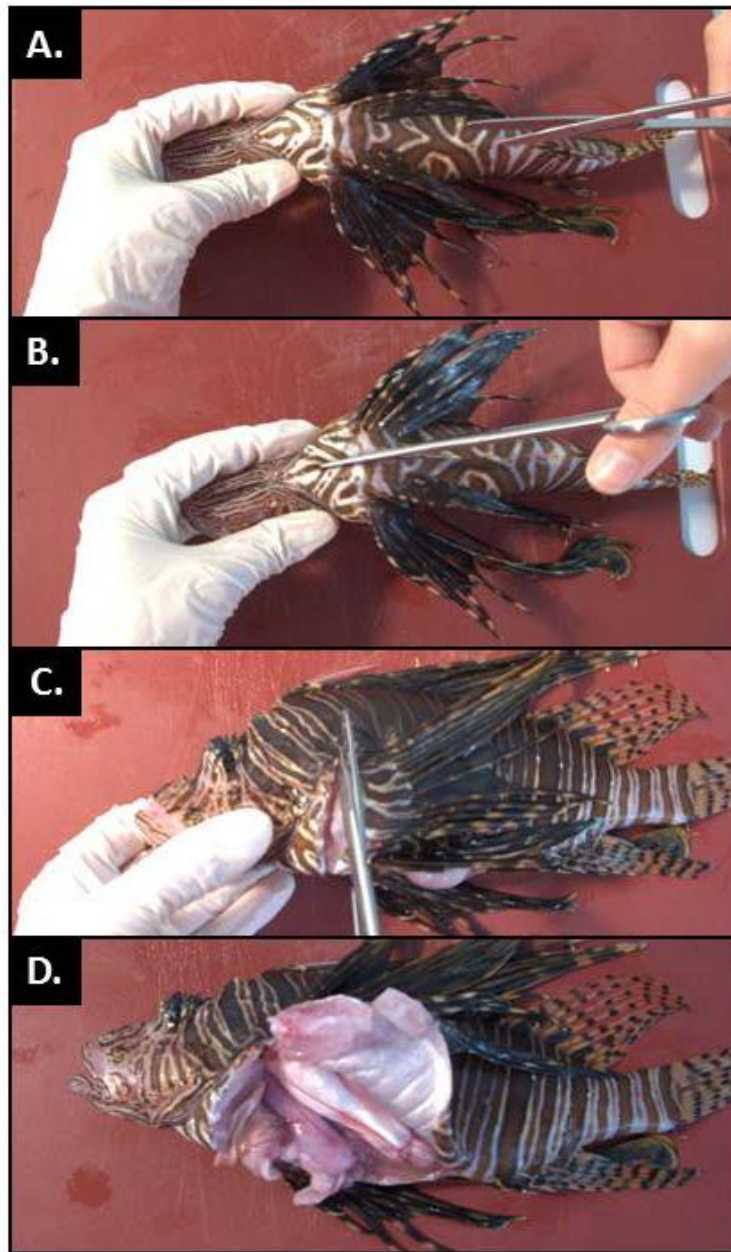


Fig. 6. Opening the lionfish's gut cavity. A) A shallow incision from urogenital opening towards the base of the pelvic fins (pelvic girdle). B) As you approach the pelvic fins, a deeper cut will be required to sever the pelvic girdle. C) Cutting along the rear edge of the gill arch toward the dorsal fin. D) Lifting the flank to expose the gut cavity and internal organs, cutting through any minor connecting tissue as needed.

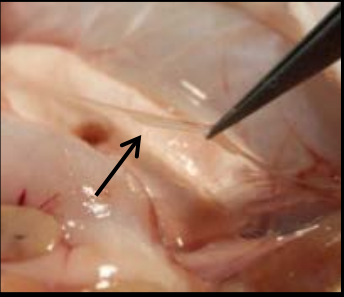
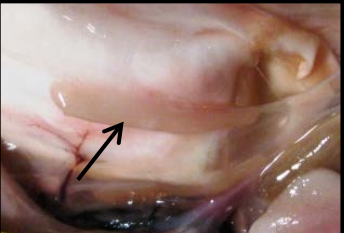
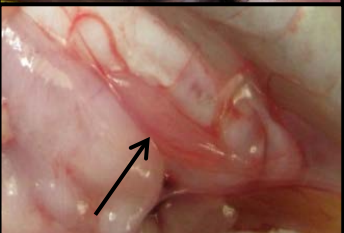


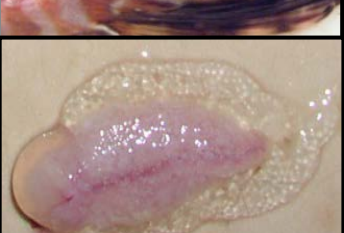

## Gender Identification and Reproductive Staging

Using a dull dissecting probe or finger, move away stomach, liver and fat to expose the swim bladder which lies along the dorsal wall of the body cavity (Fig. 2B). Identify gonads lying along the ventral side of the swim bladder (Fig. 2C). Avoid confusion with swim bladder muscle tissue which lies along the dorsal edge of the swim bladder (Fig. 2D). Gonads of smaller fish may be identified by looking for the presence of a thin blood vessel leading into and out of the gonad. Use a magnifying glass or dissecting microscope to locate lionfish gonads in small individuals as needed.

Using information on the size of the lionfish specimen, and the size and appearance of its gonads greatly aids in gender and reproductive stage identification. Immature gonads from both sexes are threadlike. As a result, testes are largely indistinguishable from immature ovaries and may be misidentified without histology in specimens smaller than 180 mm TL (Table 2A). For specimens greater than 180 mm TL, immature testes, appearance and size of the gonads can be used to determine reproductive status (Table 2B).

Gonads may be removed, weighed and stored in 10% neutral buffered formalin solution for histological examination. For long term storage, gonads that have been fixed in formalin may be transferred to 95% ethanol. Gonads that have been previously frozen may not provide accurate histological information because of cellular damage caused during freezing.

Table 2. Sex determination and gonad staging key for lionfish.

Fish length (TL)	Appearance	Gender	Stage description	Stage	Image
<180 mm	Gonads are oval masses, cream-pink in colour, with ratio of length:width less than 2.	Female	Additional information required to determine reproductive stage.	Immature (virgin) or Early Developing	See Immature or Early Developing
	Gonads elongated with ratio of length:width greater than 2.	Histology required to distinguish between male and female.	Clear, threadlike structures 1-3 mm in diameter and 5-10 mm in length. Immature ovaries are largely indistinguishable from immature testes.	Immature (virgin)	
>180 mm	Gonads elongated with ratio of length:width greater than 2.	Male	Testes appear threadlike; 1-3 mm in diameter and 5-10 mm in length.	Immature (virgin)	
			Testes appear as cream-colored with well-defined edges. Testes are typically not larger than 10 mm in diameter and 20 mm in length in the largest of specimens.	Spawning capable	
	Gonads are oval masses, cream-pink in colour, with ratio of length:width less than 2.	Female	Ovary is cream colored and round with no edges. Width may vary from 5 - 15 mm. Eggs not visible macroscopically. Ovary is more firm than during the Developing stage.	Early developing	
			Ovary cream colored with some pinkish portions. Eggs visible as small white spheres. Size may vary from a width of 15 mm to 30+ mm. No gelatinous mucus visible around periphery.	Developing	
			Ovary large with clear gelatinous mucus containing visible eggs peripheral to central stroma. Size may vary from a width of 15 mm to 30+ mm.	Spawning capable	
			Large number of clear eggs encompassed in gelatinous mucus visible along periphery of the ovary. Note: ovary wall is removed in picture.	Actively spawning	

### Interstitial fat deposits

Interstitial fat deposits appear as white, waxy bodies and masses around the stomach and intestines (see Fig. 2 for orientation). Using dissecting scissors and forceps, carefully cut fat away from the intestines and remove any other large fat deposits from the gut cavity (Fig. 7A). Partially fill a 50-ml graduated cylinder with freshwater and note the volume at the meniscus. Completely submerge the extracted fat deposits in the graduated cylinder and record the final volume of fat and water. The difference between final and initial volume is the volume of the specimen's interstitial fat; record this value to the nearest 1ml (Fig. 7B).

Note: In fish that have warmed to room temperature, fat may begin to liquefy and become difficult to accurately handle or remove. It is recommended that fish be refrigerated or stored on ice prior to dissection.



Fig. 7. A) Removal of interstitial fat deposits from intestines and B) measurement of interstitial fat volume.

### Stomach contents

Before opening the stomach, ensure that prey items or parts of prey are not protruding from the esophagus by looking into the mouth of the lionfish. Locate the stomach (Fig. 2). Using dissecting scissors sever the esophagus where it terminates (Fig. 8A) taking care not to cut any stomach items that may be protruding into the esophagus. Holding the esophagus closed with fingers or forceps, cut the stomach free from other minor tissue membranes and intestines. Remove the stomach from the body cavity and place it on a clean surface.

Insert scissors into the esophageal opening of the stomach and make a careful shallow cut along the length of the stomach wall to the intestine opening (Fig. 8B and C). Invert the stomach and carefully remove all prey items and place them onto clean surface for sorting and identification. Identify each prey item to the lowest taxonomic level possible and measure the total length of each individual prey item where possible (Fig. 8D). Use visual references guides



as needed to assist with visual identification of fish prey (e.g., Humann and DeLoach, 2002; ReefNet Inc. 2007). For prey items that are too digested to discern body shape (and thus length), length estimation is not possible. Score the digestion level of each prey item using the description in Table 3. For all prey items, use a 10-ml graduated cylinder, measure the volume of each prey by water displacement (same method described for measuring the volume of interstitial fat). Preserve prey items either frozen or fixed in 95% ethanol.

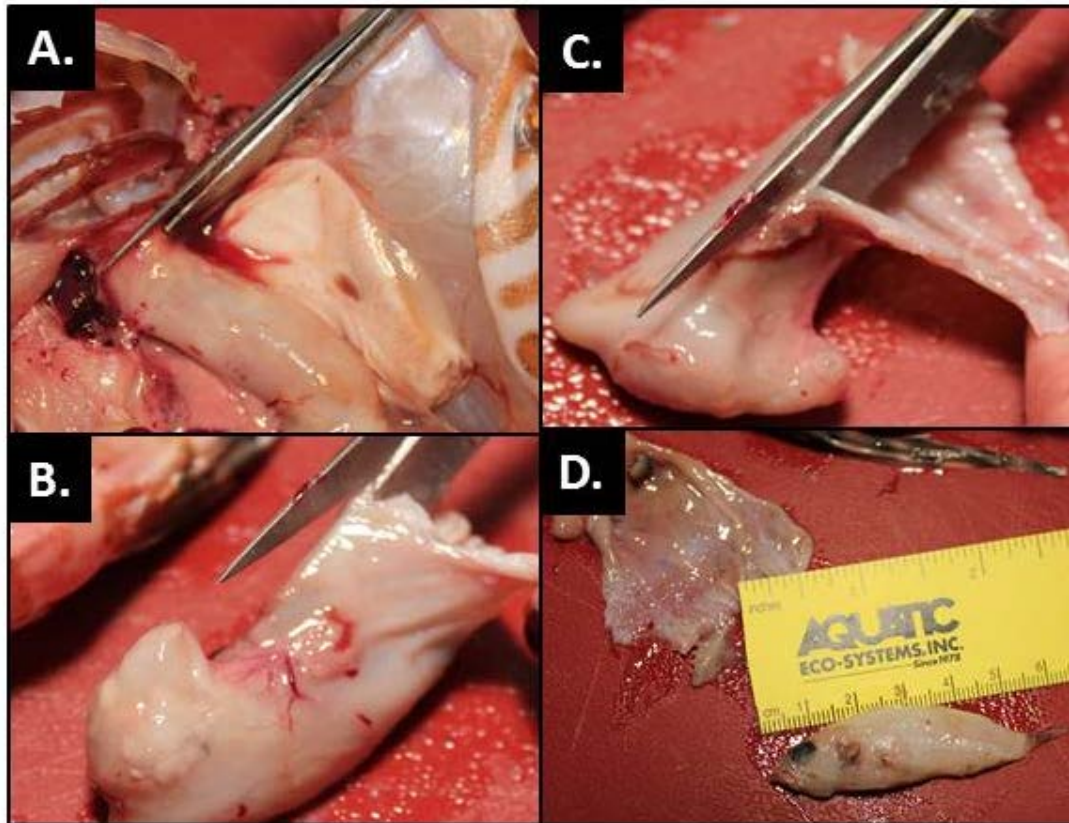


Fig. 8. Stomach dissection and contents analysis. A) Using dissecting scissors sever the esophagus where it terminates. B) Insert scissors into the esophageal opening of the stomach. C) Make a shallow cut along the length of the stomach wall to the intestine opening. D) Invert the stomach and remove all prey items; placing prey onto a clean surface for sorting and identification.

Table 3. Five-point scale for scoring the digestion level of individual prey items removed from the lionfish stomach.

Score	Description	Identification resolution
1	No degradation or digestion; prey item appears freshly consumed	Species
2	Minor degradation to fin rays and scale pigmentation	Species
3	Substantial degradation to external structures such as fin rays and scale pigmentation	Family
4	Major degradation: parts of body flesh missing, no pigmentation, length measurement not possible	Vertebrate/invertebrate
5	Prey item fully digested and reduced to mush-like condition	Visual identification not possible

#### Otolith removal

Otoliths, or ear stones, are small bone-like structures in the otic bulba of the cranial cavity of fish. As a fish grows, deposits are made on otoliths in the form of rings. These rings can be used for determining fish age and growth rates (Fig. 9A through C). Otoliths are composed of calcium carbonate and are brittle. Care must be taken during removal to avoid damaging them. There are three otoliths on each side of the otic bulba in the cranial cavity (grouped into pairs). Sagittal otoliths are the largest and their dissection is described below and in Fig. 10.

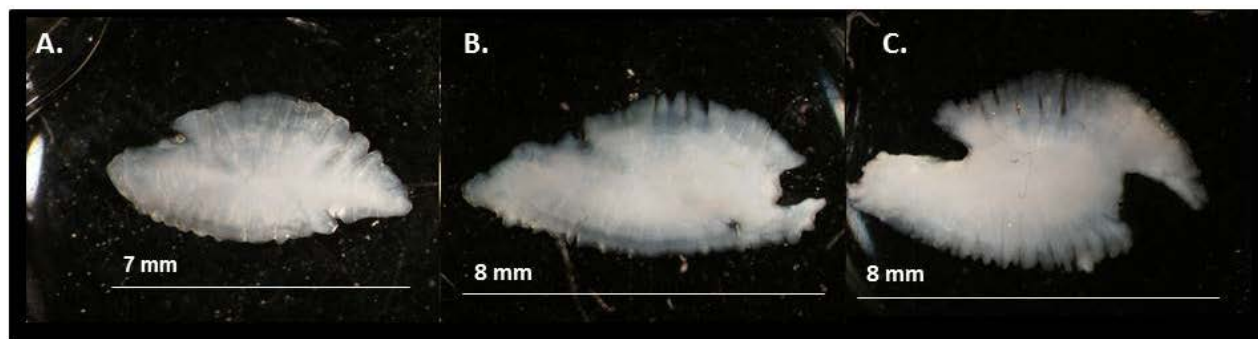


Fig. 9. Ontogenetic change in sagittal otolith shape, taken from lionfish of A) 250 mm, B) 325 mm and C) 357 mm total length. Photo credit: Jennifer Potts.

There are several ways to perform otolith removal. Here we provide instructions for otolith removal using a technique that involves removal of the head for easy access to the sagittae. In some cases where trauma to the head of the carcass is an issue, other methods may be more appropriate (e.g., trophy fish caught during tournaments). Detailed instructions for alternate techniques of sagittal otolith removal can be found in Secor et al (1991).

Remove the specimen's head by cutting vertically from between the head spines and the first dorsal spine to the isthmus of the gill opening using a large, sharp knife. Turning the head nose down following severance of the spinal cord (Fig. 10A) reduces difficulty in cutting through cartilage. Holding the head dorsal-side down, grasp gill filaments and arches and sever their attachment to the roof of the oral cavity (Fig. 10B). Fold the gill arches forward to reveal the cranial cavity, which can be easily located by running two fingers along both sides of the spinal cord anteriorly until a slight bulge is felt (the cranial cavity; Fig. 10C ). Place two fingers on the cranial cavity and make a cut on the posterior side of the cavity down through the spine (Fig. 10D). This incision allows access to the cranial cavity which contains the sagittal otoliths. Proper position of this incision is critical. Cutting too far forward into the cranial cavity will dislodge the otoliths and make them difficult to recover and cutting too shallow will prevent access to the cavity (Fig. 10E). Using a pair of fine-tipped forceps, reach into the cranial cavity at an oblique angle ( $\sim 30^\circ$ ) to the dorsal plane, holding the forceps perpendicular to the dorsal plane. Remove the otoliths by reaching into the cranial cavity. Otoliths are free-floating inside the cranial cavity and resistance felt while searching inside the cranial cavity indicates that the structure held is not an otolith (Fig. 10F). Once removed, clean and dry the otoliths and place in a storage container.

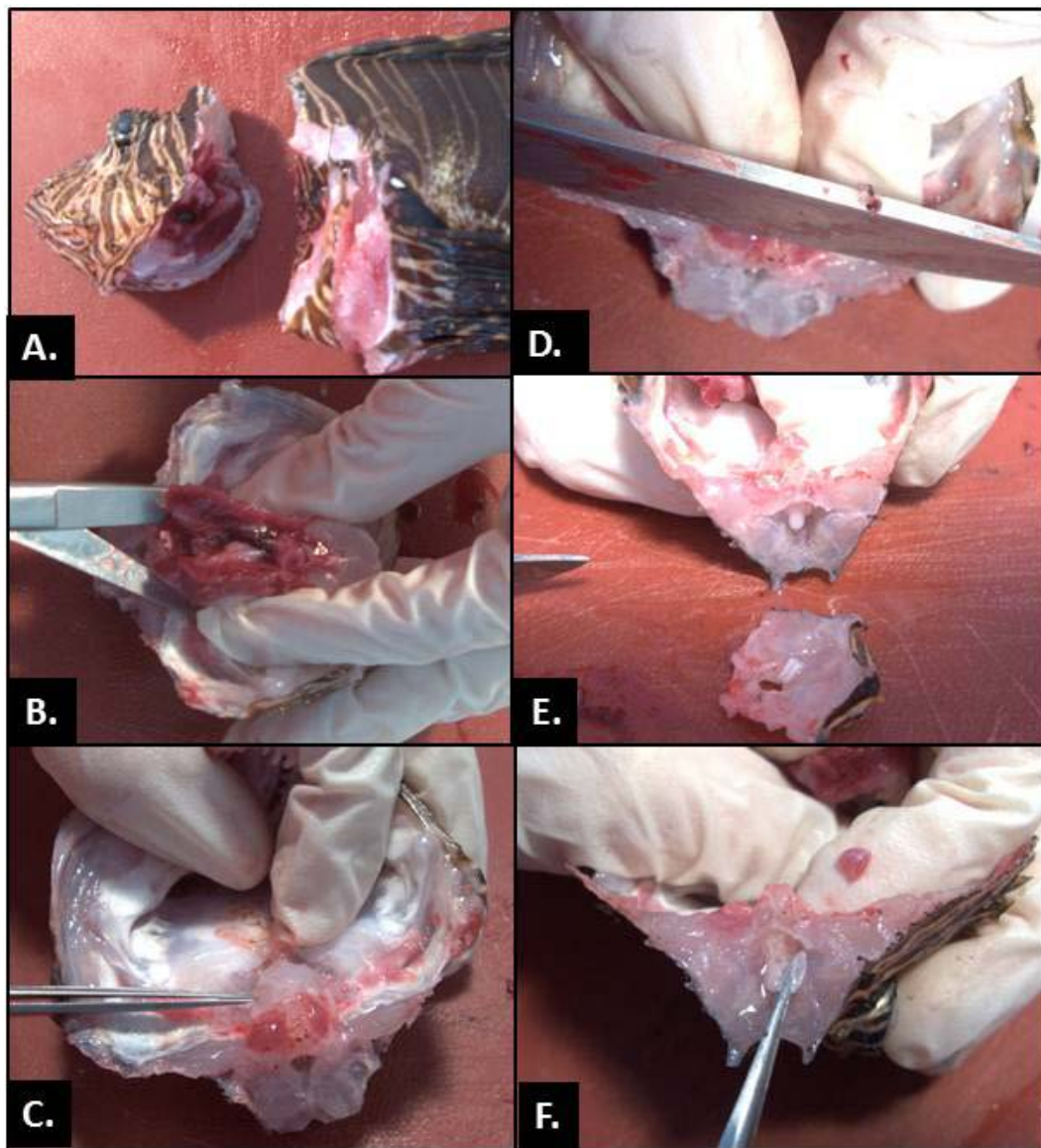


Fig. 10. Sagittal otolith removal. A) Sever the spinal cord between the head and the first dorsal fin ray. B) Grasp the gill filaments and arches and sever their attachment to the roof of the oral cavity. C) Locate the cranial cavity by running two fingers along both sides of the spinal cord anteriorly until a slight bulge is felt. D) Make a cut on the posterior side of the cavity down through the spine. This incision allows access to the otic bulba, which contains the sagittal otoliths. E) Brain matter (white, soft tissue) will often be exposed by opening the cranial cavity. F) Reach gently into the cranial cavity to remove the free-floating otoliths.



## **Acknowledgements**

This work provides research findings supported by the NOAA Aquatic Invasive Species Program, NOAA National Centers for Coastal Ocean Science, Reef Environmental and Education Foundation, Natural Sciences and Engineering Research Council of Canada, and Simon Fraser University. We thank N. Brown-Peterson, M. Albins, I. Côté, C. Buckel, J. Potts, P. Marraro, M. Fonseca, and K. Riley for their helpful review of this manuscript.

## Literature Cited

- Akins, L. In press. Control strategies: Tools and techniques for local control. *In* Morris, J.A., Jr., editor. Strategies and practices for invasion lionfish control and research: A guide for managers. Gulf and Caribbean Fisheries Institute, Marathon, FL, USA.
- American Association of Veterinary Medicine. 2007. AVMA Guidelines on euthanasia. [http://www.avma.org/issues/animal\\_welfare/euthanasia.pdf](http://www.avma.org/issues/animal_welfare/euthanasia.pdf). Accessed January 2012.
- Badillo, R. B., W. Banner, J. A. Morris, Jr., and S. E. Schaeffer. 2012. A case study of lionfish sting-induced paralysis. *AACL International Journal of Bioflux Society* 5: 1-3.
- Blessing, J. J., J. C. Marshall, and S. R. Balcombe. 2010. Humane killing of fishes for scientific research: a comparison of two methods. *Journal of Fish Biology* 76: 2571-2577.
- Borski, R. J. and R. G. Hodson. 2003. Field research and the institutional animal care and use committee. *Institute for Animal Research Journal* 44: 286-294.
- Humann, P. and N. DeLoach. 2002. Reef fish identification: Florida, Caribbean, Bahamas. 3<sup>rd</sup> Edition. New World Publications, Jacksonville, FL, USA.
- Kelsch, S. W. and B. Shields. 1996. Chapter 5. Care and handling of sampled organisms. *In*, Murphy, B. R. and D. W. Willis, editors. Fisheries Techniques. 2<sup>nd</sup> Edition. American Fisheries Society, Bethesda, MD, USA.
- Neiffer, D. L. and M. A. Stamper. 2004. Fish sedation, anesthesia, analgesia, and euthanasia: Considerations, methods, and types of drugs. *Institute for Animal Research Journal* 50: 343-360.
- ReefNet Inc. 2007. Reef fish identification: Florida, Caribbean, Bahamas. 4<sup>th</sup> Edition Interactive DVD. New World Publications, Jacksonville, FL, USA.
- Secor, D. H., J. M. Dean, and E. H. Laban. 1991. Manual for otolith removal and preparation for microstructural examination. Technical publication 1991-01 Belle W. Baruch Institute for Marine Biology and Coastal Research, Georgetown, SC, USA. <http://www.cbl.umces.edu/~secor/manual/chap4.pdf>. Accessed January 2012.
- Soltani, M., G. H. Marmari, and M. R. Mehrabi. 2004. Acute toxicity and anesthetic effects of clove oil in *Penaeus semisulcatus* under various water quality conditions. *Aquaculture International* 12: 457-466.
- Wilson, J. M., R. M. Bunte, and A. J. Carty. 2009. Evaluation of rapid cooling and Tricaine Methanesulfonate (MS222) as methods of euthanasia in Zebrafish (*Danio rerio*). *Journal of the American Association for Laboratory Animal Sciences* 48: 785-789.

## Appendix I: Example template - Lionfish dissection data sheet

[illegible]

## Appendix II: Example template - Lionfish stomach contents data sheet

[illegible]

## Appendix III: Dissection Equipment List

### Dissection Equipment List

*\*quantity of each item will vary with number of specimens*

Puncture-resistant gloves

#### *Euthanasia*

Per 10 L seawater:

5 ml Clove oil

45 ml Isopropyl or ethyl alcohol

OR

4 L ice

#### *Dissection*

95% Ethanol

Formalin

Lionfish specimen data sheet

Lionfish stomach contents data sheet

Large dissection board

Large sharp kitchen knife

Fine-tipped forceps (2 pair)

Dissecting scissors (1 pair)

Paper towels

Volumetric flasks (10 ml and 50 ml)

Pipette

Sharpie permanent pen


Specimen sample labels (Underwater paper cut into 2" x 2" sections)

Screw-capped glass sample vials (~5 ml volume)

Whatman filter paper

Small plastic sample bags (~10 ml volume)

Vials or envelopes for otoliths



### **What is the Lionfish Tissue Repository?**

The Lionfish Tissue Repository (LTR) is a multi-national collaborative program intended to maintain and provide tissue samples for research into the ecological and evolutionary processes driving the ongoing invasion of lionfish (*Pterois spp.*) in the Caribbean and western Atlantic.

### **Who contributes to repository?**

Scientists, managers and fishers throughout the western Atlantic have contributed tissue samples to the growing database. Large collections of samples from the eastern United States, Bahamas and Cayman Islands have been contributed by organizations such as NOAA, Reef Environmental Education Foundation (REEF), Oregon State University, George Washington University, and the Cayman Islands Department of the Environment.

### **Who manages the repository?**

The repository is jointly managed by NOAA and Reef Environmental Education Foundation (REEF). There are currently well over 3,000 genetic tissue samples spanning nearly a decade collected from lionfish throughout the invaded Caribbean and eastern coast of the US. As samples continue to accumulate, we expect the tissue repository will yield a uniquely detailed genetic and ecological history of a major invasion.

### **Who is using the repository?**

The intent of the LTR program is to carry out collaborative research that will help scientists and natural resource managers understand the invasion (and invasion ecology/evolution in general), identify mechanisms for mitigating the invasion impact, and prevent future marine invasions. We anticipate that the LTR will be most useful for the study of lionfish genetics or foraging ecology (e.g. stable isotope ecology). There may, however, be additional applications not yet considered. By maintaining the LTR, we preserve the opportunity to address future research questions in an opportunistic manner.

*For additional questions about on-going research, contact the project principal investigator Dr. James Morris at [James.Morris@noaa.gov](mailto:James.Morris@noaa.gov) or visit*

<http://www.ccfhr.noaa.gov/stressors/lionfish.aspx>.

---

United States Department of Commerce

John E. Bryson  
Secretary

National Oceanic and Atmospheric Administration

Jane Lubchenco  
Undersecretary of Commerce for Oceans and Atmosphere  
and NOAA Administrator

National Ocean Service  
David Kennedy  
Assistant Administrator for Ocean Services and Coastal Zone Management

